

23  
Pant many breeders simply explain as  
growing pains & although pups typically  
out grow this it is very common and  
a real explainable medical condition

## Disease Conditions in Small Animals

---

### Panosteitis

Panosteitis is a very common condition of long bones in large breeds of young dogs, especially the German shepherd and basset hound. The condition is also called eosinophilic panosteitis, osteomyelitis, enostosis, fibrous osteodystrophy, juvenile osteomyelitis,<sup>1</sup> and "eo pan" or "long-bone disease" by breeders.

Although this disease causes severe lameness, it is self-limiting, and there is no permanent impairment. Therefore, because the condition gets better "by itself," intensive investigations of the various stages of this disease have been lacking. Many contradictions exist as to its clinical features.

The etiology of panosteitis is unknown, although infection, metabolic disease, endocrine dysfunction, allergy, autoimmune mechanisms, parasitism, and hereditary factors have been postulated.<sup>1</sup> Viral infection appears the most probable cause of panosteitis.<sup>2</sup> In a recent review of this condition,<sup>3</sup> there is no new information as to its cause.

### Clinical Signs

The clinical picture is that of a healthy dog with lameness of acute onset but no history of trauma. Males are affected four times more often than females.<sup>4</sup> The lameness may be marked, and often the dog will "carry" or favor the limb. This lameness may last a few days to several weeks.<sup>4</sup> In about 53 percent of cases, other limbs have become involved, thereby characterizing the condition as causing a "shifting leg lameness."<sup>5</sup> These recurring bouts usually subside by the time the animal reaches 2 years of age.<sup>1</sup> However, dogs up to 5 years of age have incurred panosteitis.<sup>5,6</sup>

### Examination

Gentle palpation along the distal, middle, and proximal areas of long bones may elicit exquisite pain when the involved area is reached, even in stoic animals. This reaction may consist of crying out, wincing, pulling the leg away, or, occasionally, snapping at the examiner. When palpating, the clinician's fingers should push aside muscle bundles (especially of the humerus and femur) so that bone is reached prior to squeezing. This avoids misinterpretation arising from hurting normal muscle tissue trapped in the palpation.


Depending on when thorough veterinary attention is sought and how elaborate the workup completed, other factors may be present, such as fever,<sup>1,2</sup> muscle atrophy,<sup>4</sup> eosinophilia,<sup>1,4</sup> decreased activity, and inappetence. Others have disclaimed the occurrence of fever, muscle atrophy,<sup>6</sup> and eosinophilia.<sup>4</sup> Eosinophilia has been reported to be seen only in the first 2 days of clinical signs.<sup>1</sup>

### Radiographic Signs

Radiographically, the disease may be separated into three stages.<sup>6</sup> Often, the clinician sees the case in the middle phase and the other stages only during extensive studies of this condition.

**EARLY PHASE** ■ Although the limb may be asymptomatic, radiographic changes may be detected during a survey of all the long bones. These consist of blurring and accentuation of trabecular patterns, best seen at the proximal and distal ends of the diaphysis (Figure 23-1). The contrast between the cortex and medullary canals is diminished. In some cases, a few granular densities are seen.

**MIDDLE PHASE** ■ Patchy, mottled, sclerotic-looking densities appear, especially around the nutrient foramen in the early stages (Fig. 23-2). In some cases, the entire diaphysis is involved; in others, there may be only pea-size lesions (Fig. 23-3). In a third of panosteitis cases, the periosteum becomes involved. Initially, a subtle roughening appears that becomes more dense within 1 or 2 weeks and eventually becomes as dense as the cortex (Figs. 23-2 and 23-3).



**FIGURE 23-1.** Early stage of eosinophilic panosteitis in the humerus of a 9-month-old male German shepherd. Granular densities are seen.



**LATE PHASE** ■ In the process of recovery, the medullary canal attains normal density while the coarse trabecular pattern remains. In about a third of the cases, the cortex remains thicker than normal. A few granular densities may be present. It may require several months for these changes to disappear completely. In general, the lesions affect the central part of the radius, the proximal third of the ulna, the distal and central parts of the humerus, the proximal third of the tibia, and the central and proximal parts of the femur.

### Histopathology

Histopathological findings<sup>6</sup> of the lesions consist of accentuation of osteoblastic and fibroblastic activity in the periosteum, endosteum, and marrow. Fibrosis occurs in the marrow. There is evidence of neither acute or chronic inflammation nor malignancy. In highly mature lesions, the cortical thickening consists of thickened lamellar bone with haversian systems, whereas in immature lesions, cellular fiber bone is present with many osteoblasts and osteoclasts.

### Differential Diagnosis

Differential diagnosis includes osteochondritis dissecans, fragmented coracoid process, ununited anconeal process, hip dysplasia, cruciate disease, coxofemoral luxation, and fractures. When there is a shifting leg lameness, other conditions such as rheumatoid arthritis, systemic lupus erythematosus (SLE), or bacterial endocarditis must be considered. The diagnosis of panosteitis is determined by palpation and radiography.

### Treatment

Treatment is symptomatic to relieve pain by using aspirin, corticosteroids, and other agents. None of these has been documented to hasten the resolution of the condition.<sup>1,3</sup>

## NUTRITIONAL DISORDERS

Although nutritional problems affecting bone and muscle are beyond the scope of this text,<sup>1,7-11</sup> some clinical situations that may confront the orthopedist are considered.

### Clinical Problems

There are three clinical problems we see: obesity, consequences of the all-meat diet, and oversupplementation in large and giant breeds of dogs.

#### **Obesity**

Although obesity has not been proved to cause osteoarthritis, at least in mice,<sup>12</sup> common sense tells us that excessive weight on injured or congenitally deformed joints or spinal conditions can affect musculoskeletal performance. Prevention of obesity is obviously accomplished more readily than treatment. Interesting clinical studies in people have shown that obesity precedes and increases the risk of osteoarthritis of the knee (especially women)<sup>13,14</sup> and probably results from mechanical stresses.<sup>15</sup> In addition, other studies suggest that

weight loss can both prevent the onset of symptomatic osteoarthritis of the knee<sup>16,17</sup> and alleviate pain when present.<sup>16</sup> If the veterinary clinician observes patients gaining weight, or if an animal has a potential for arthritis or back problems or becomes neutered, the client should be warned to watch the animal's weight carefully and to cut back food intake before weight gain becomes unmanageable. In known periods of inactivity (e.g., the winter months, or cessation of the hunting season), food intake should be diminished.

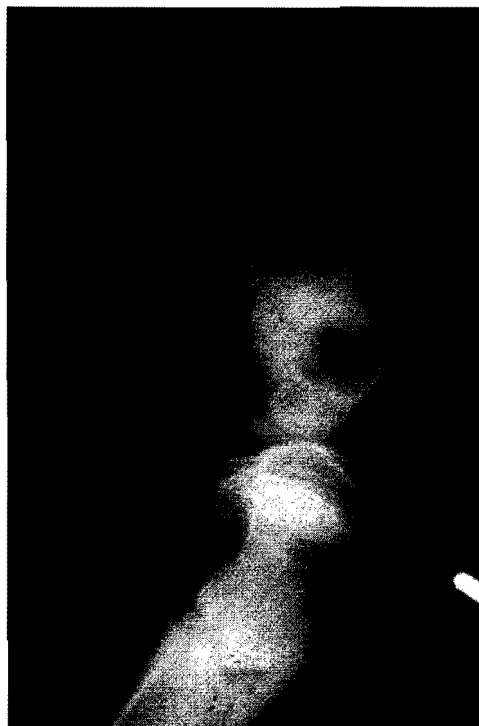
If an animal is obese, the endocrine system, especially the thyroid, should be examined. For a "diet," we usually recommend cutting the total daily caloric intake by one third to one half in order to reduce the animal's weight. Canine vitamin supplementation may be administered to alleviate the owner's apprehension concerning dietary restriction. Often, if the owner is sincere and conscientious, decreasing the amount of presently fed food by one third to one half is all that is necessary. Owners (even those who are themselves overweight) seem to understand and accept "the more weight your pet carries, the more it abuses its bad joint, which could potentially hasten joint destruction, necessitating surgery or leading to a painful life." When this does not seem to be effective, prescribed reducing diets may be tried. Our usual goal is to achieve a conformation in which there is an observable indentation or "waist" along the flank region and the presence of individually palpable ribs. Some clients may need to be told, "Your dog needs to lose 4 pounds," instead of these guidelines. For a lighter weight breed, the owner may monitor progress using a bathroom scale at home.

#### ***The All-Meat Diet***

Publicity concerning all-meat diets has been widespread enough that the syndrome is rarely seen today. Low in calcium and high in phosphorus, this diet has the tendency to cause secondary nutritional hyperparathyroidism (SNH), a condition in which the parathyroids are stimulated to secrete parathormone. This hormone increases the resorption of calcium from bone in order to maintain proper serum levels. In the young animal, the result may be loss of skeletal density and thinning of the bone cortex. Lameness or pathological fracture may result (Fig. 23-4). In an adult animal that is fed an all-meat diet, the process is slow and can result in osteopenia. Treatment involves feeding the animal a balanced commercial diet as well as supplementation with calcium.

#### ***Hypernutrition and Oversupplementation***

The most perplexing nutritional problem facing the orthopedist is presented when a breeder asks the veterinary clinician to test serum calcium and phosphorus levels in a young dog of large or giant breed that has poor bony conformation. Although it may appear that improper nutrition is to blame, this may or may not be the answer. A few points are worth emphasizing in this regard. In giant breeds, the phosphorus may be twice as high in the dog 3 to 6 months old as in the adult (8.7 mg/100 ml versus 4.2 mg/100 ml). The calcium may be slightly higher in a younger animal (11.1 mg/100 ml versus 9.9 mg/100 ml for an adult).<sup>7</sup> In those dogs with known dietary excesses or imbalances of calcium and phosphorus, the serum calcium and phosphorus levels usually are in the normal range as a result of the dog's homeostatic mechanisms, if the parathyroid gland is working properly. More sensitive indicators of dietary imbalance are the quantities of calcium and phosphorus excreted in the urine over 24 hours and the creatinine clearance ratios.



**FIGURE 23-4.** Five-month-old male Gordon setter with pathological fracture of the tibia from secondary nutritional hyperparathyroidism. Note the thin cortices of the femur. This dog was fed a balanced home diet by a breeder using egg shells (which are not absorbed in the canine intestine) for the calcium source.

Most commercial dry dog foods contain the proper quantities of and balance between calcium and phosphorus. People owning large breeds feel that this commercial diet may be good for the normal "run-of-the-mill" dog, but not for their dog, which is going to be large. Often the owner feeds a mixture of foods suggested by the breeder, for whom the diet produced champions. These mixtures include vitamins, dicalcium phosphate, bone meal, high-protein cereals, meat, milk, cottage cheese, eggs, wheat germ, and other nutrients. This highly palatable diet may lead to an ingestion of excessive quantities of nutrients that can lead to a nutritional imbalance. Young Great Danes fed a balanced diet ad libitum had accelerated bone growth, sinking of the metacarpophalangeal joints, lateral deviation of the forepaws (valgus deformity of the carpus), cow-hocked rear limbs, enlargement of the distal radial and ulnar metaphyses, enlargements of the costochondral junctions, pain, arched backs, and inactivity. Those dogs fed two thirds of the quantity of protein and calories of the other group had slower bone growth and better conformation, and they were more active and playful.<sup>9</sup> It is therefore wise for the veterinarian to discuss diet with the owners of these large breeds. The importance of slow bone growth should be stressed, and the owners should be warned not to push their dogs nutritionally.

Signs of overnutrition may be mistaken for "rickets" and therefore improper acceleration of the plane of nutrition prescribed. Rickets is extremely rare and has been seen usually only under starvation or research conditions.

The valgus deformity of the carpus may correct itself when the diet is changed while the dog is still growing. Severe deformities, however, may require corrective osteotomy after skeletal maturity is complete.